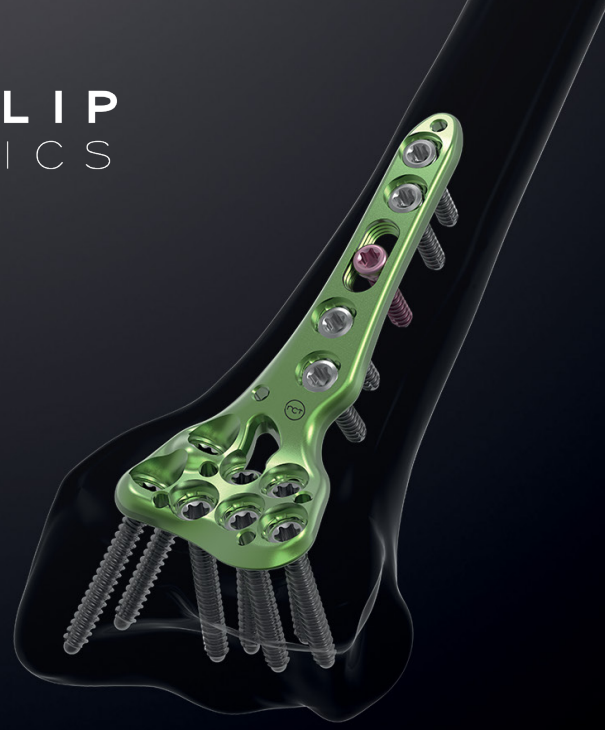



CASE STUDY

OVER 6-WEEKS OLD COMMINUTED & INTRA-ARTICULAR DISTAL RADIUS FRACTURE : INTEREST OF A COMBINED APPROACH WITH A XPERT 2.4 PLATE AND THE SPANNING PLATE

PHYSICIAN PROFILE

Dr KESSLER Michael

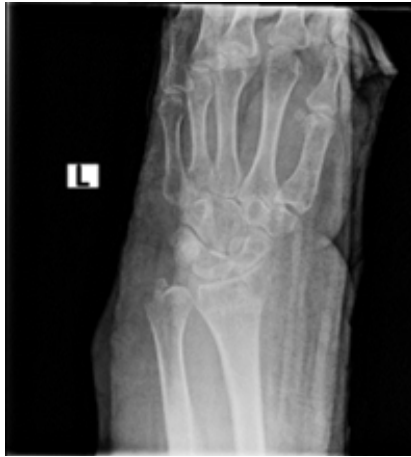Hand surgeon, MedStar Georgetown University Hospital, Washington D.C. (USA)

Active member of : ASSH, AAOS, AOA

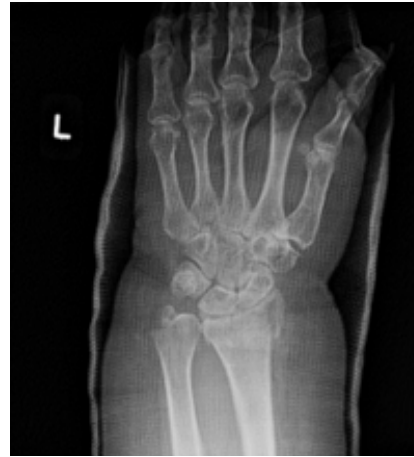

PATIENT HISTORY

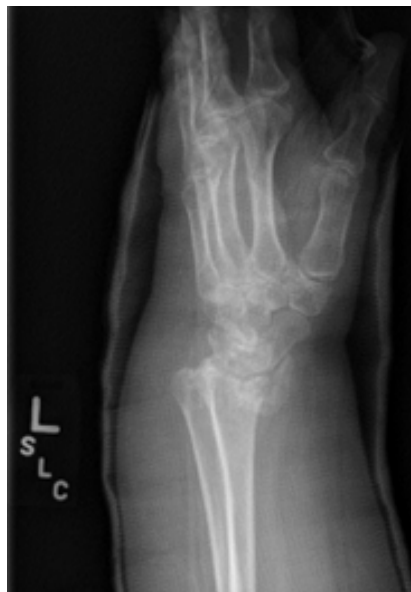The patient is a woman in her sixties, with a low level of activity, who suffered an intraarticular, comminuted distal radius and ulna styloid fracture (AO 23-C2). She was initially followed by another physician and had a non-operative treatment. After 6 weeks, she reconsulted with a lot of pain (7/10) and it has been decided that she needed surgery. Her distal radius could have been fixed with a standard distal radius plate but due to her obesity (IMC > 35,) and her decreased overall mobility, it was wiser to consolidate the set-up with the spanning plate to help distribute the force over a greater area while still achieving an anatomic reduction with the standard distal radius plate.



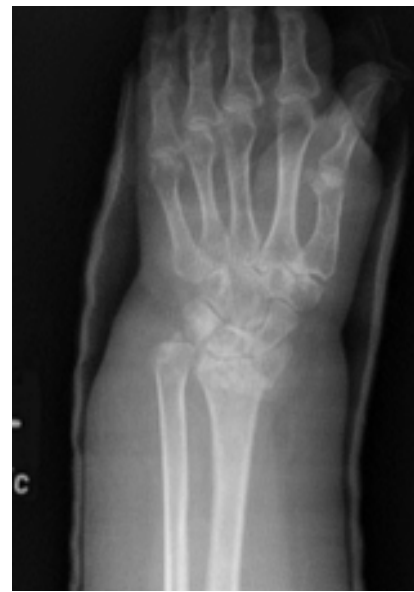PA x-ray post injury



After 2 weeks cast



After 4 weeks cast - lateral view

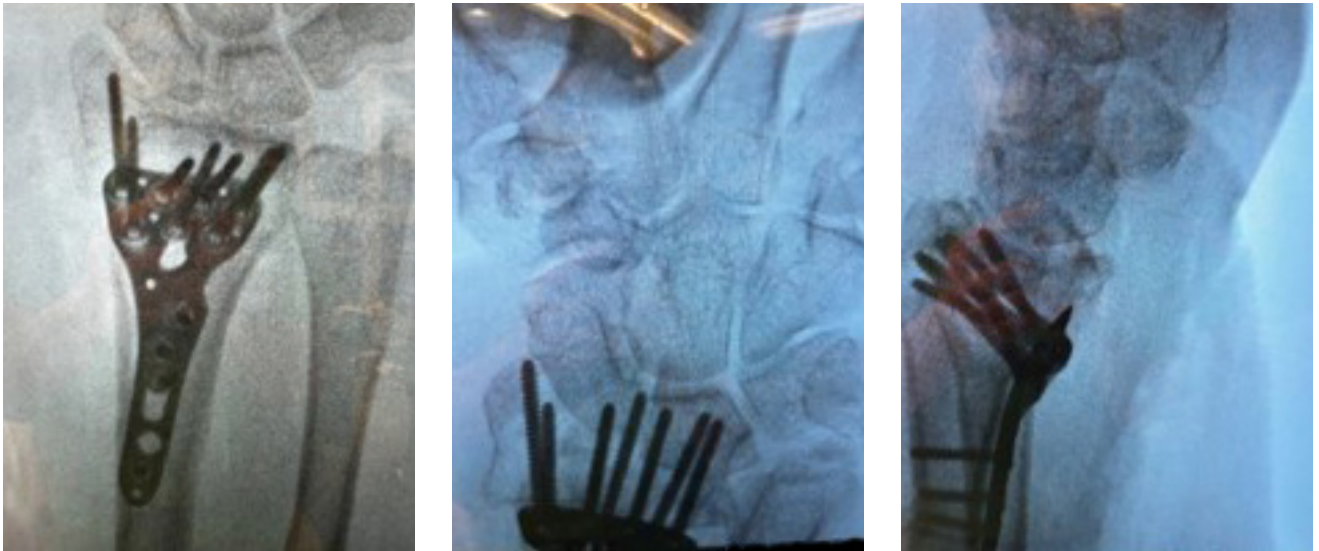

After 4 weeks cast

SURGICAL TREATMENT

The primary consideration for the surgery was to make the construct strong enough to withstand full weightbearing to the affected wrist during the healing process of the fracture. Since the fracture had occurred over four weeks prior, it has been anticipated that there would be disuse osteopenia, in addition to the osteopenia secondary to the fracture. The preoperative planning included postero-anterior, lateral and oblique x-rays.

The procedure began with a standard FCR (flexor carpi radialis) approach to the volar distal radius, with the application of a size 3 distal radius plate. During the volar fixation, it was noted that the metaphyseal bone was quite thin and did not hold the screws very well.

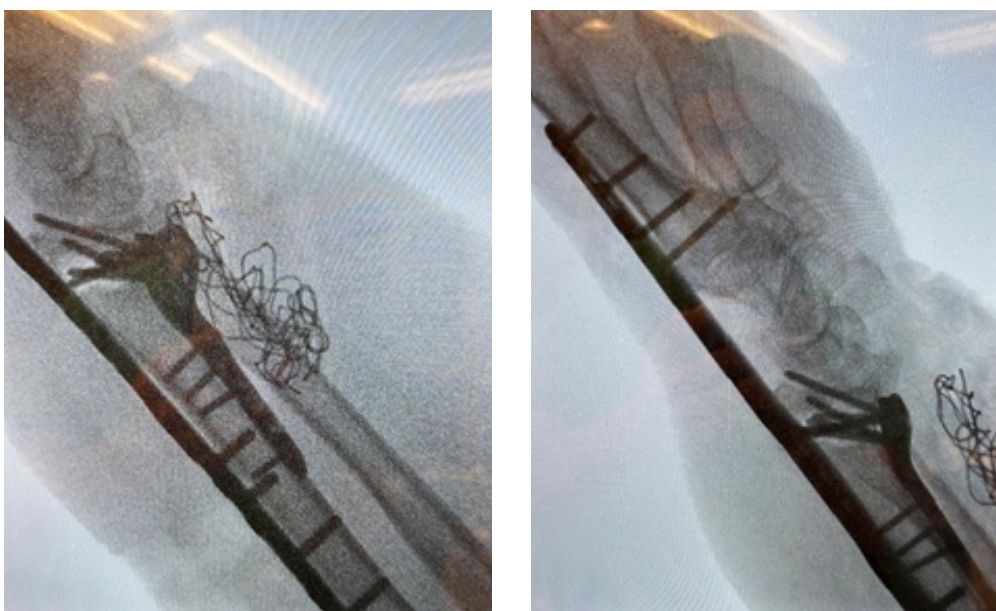


X-rays during surgery

In order to allow the patient to weight bear, it has been decided to proceed with the spanning plate as an additional form of fixation. Once the wrist was back to the normal alignment, a minimally invasive technique to approach the dorsal aspect of the hand and wrist has been used.

First, the spanning plate size was confirmed by positioning it on the dorsum of the wrist and hand, and by using fluoroscopy. Two skin incisions were made : one at the shaft of the second metacarpal and one at the diaphysis of the distal radius, approximatively proximal to where the volar plate ended.

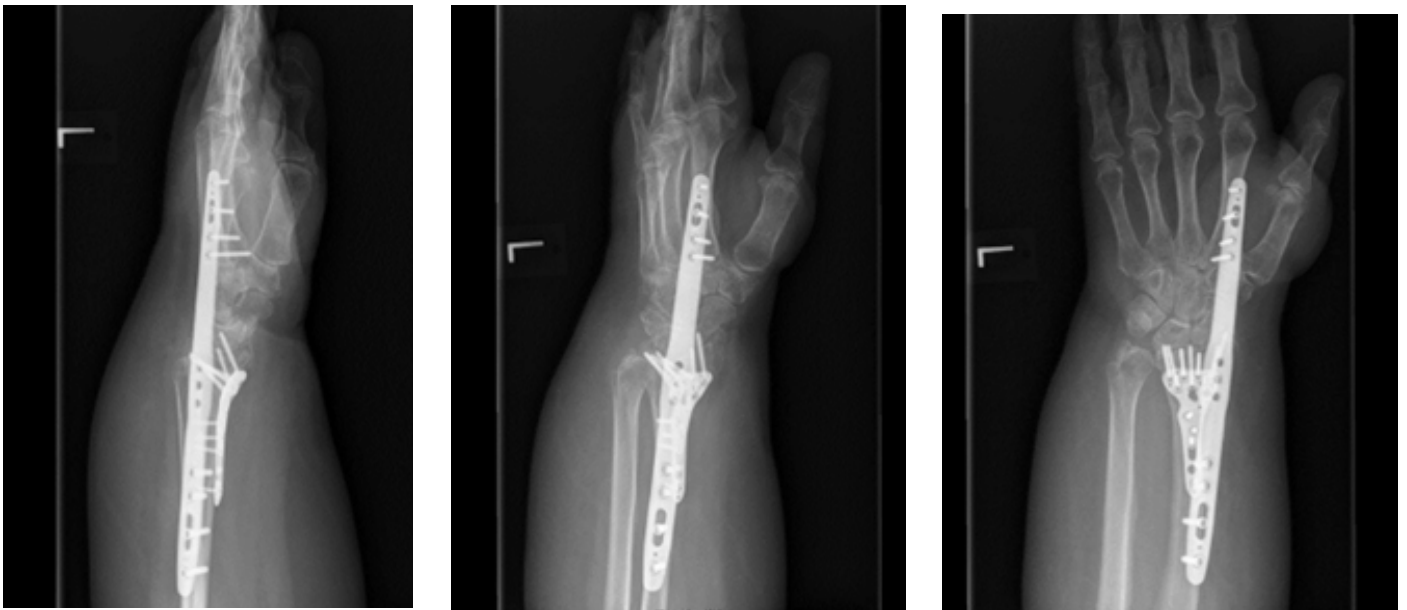Then, the plate was slid subcutaneously from proximal to distal, being sure that any of the extensor tendons were irritated or compressed. The plate was then fixed to the radius proximally and the second metacarpal distally while maintaining appropriate length, alignment and rotation of the wrist.



X-rays during surgery

POST-OPERATIVE FOLLOW-UP

The postoperative protocol included immediate Occupational Therapy for the patient's fingers and wrist to promote pronation and supination. The patient came back for her 6-weeks consultation and the X-rays showed improving healing at the distal radius metaphysis. The patient was taken to the Operating Room for hardware removal through the minimally invasive incisions, and also for a gentle manipulation under anesthesia to alleviate some of the stiffness at the radiocarpal, midcarpal and distal radioulnar joints.



Postoperative X-rays : 6 weeks after surgery

After 4 months postoperatively, the patient was able to perform all activities of daily living without assistance. She had minimal to no pain (0/10 on the visual analogue scale) at rest, or with range of motion. She was quite satisfied with her outcome and felt that she was back to performing her normal routines, as if she had never fractured her wrist in the first place.

PHYSICIAN CONCLUSIONS

The use of the Xpert Wrist Spanning plate provide the necessary stabilization to allow for immediate weight bearing in a patient with a comminuted, osteopenic fracture, who required her upper extremities to get up and down from a seated or lying position.

Benefits of the Newclip implants include the increased width and screw options at the distal radius metaphyseal level for fragment specific fixation, if needed. The increased width assured that there would not be any escape of the dorsal fragments that may have not been captured by the volar screw fixation. Color coding of implants and instruments along with instrument that works together without having to open multiple trays, makes the system easy to use. This system allows an easy identification by the scrub technician, who was not previously familiar with this specific system. The representative's presence allowed the physician to focus on patient care rather than the instrumentation.

Intended purpose: *The implants of the Xpert Wrist range are intended for fixation of hand and forearm fractures, osteotomies and arthrodeses in adults.*

Xpert Wrist 2.4 volar plates - EC: class IIb – CE1639 SGS BE

Xpert Wrist - Spanning plate - Medical device US class II. This device is not currently CE marked

NEWCLIP TECHNICS

45 rue des Garottières
44115 Haute Goulaine, France
+33 (0)2 28 21 37 12
orders@newcliptechnics.com

www.newcliptechnics.com

NEWCLIP TECHNICS GERMANY

Newclip GmbH
Pröllstraße 11
D-86157 Augsburg, Germany

+49 (0)821 650 749 40
info@newclipgmbh.com

www.newclipgmbh.de

NEWCLIP TECHNICS USA

Newclip USA
340 Tesconi Circle Suite A
Santa Rosa CA 95403, USA

+1 707 230 5078
customerservice@newclipusa.com

www.newclipusa.com

NEWCLIP TECHNICS AUSTRALIA

Newclip Australia
3B/11 Donkin Street
West End 4101, Australia

+61 (0)2 81 886 110
solutions@newclipaustralia.com

www.newcliptechnics.com

NEWCLIP TECHNICS JAPAN

Newclip Technics Japan K.K.
KKK Bldg. 502, 3-18-1 Asakusabashi
Taito-Ku, Tokyo, 111-0053, Japan

+81 (0)3 58 25 49 81
Fax: +81 (0)3 58 25 49 86

www.newcliptechnics.com

NEWCLIP TECHNICS IBERIA

Newclip Iberia
Calle Frederic Mompou, 4b
Sant Just Desvern, 08960 Barcelona, Spain

+34 938 299 526
contact@newclipiberia.com

www.newcliptechnics.com

NEWCLIP TECHNICS BELGIUM

Newclip Belgium
Derbystraat 43
1059 Sint-Denijs-Westrem

09 231 13 31
contact@newclipbelgium.com

www.newcliptechnics.com